Case of progressive intrauterine twin pregnancy after surgical treatment of cornual pregnancy

Véronique Divry, M.D.,[a] *Samia Hadj, M.D.,*[a] *Agnès Bordes, M.D.,*[a] *Anne Genod, M.D.,*[a] *and Bruno Salle, M.D., Ph.D.*[a,b]

[a] Département de Médecine de la Reproduction, Hôpital Edouard Herriot; and [b] Institut National de la Santé et de la Recherche Médicale, Unité 418, Hôpital Debrousse, Lyon, France

Objective: To report on a case of heterotopic triplet pregnancy after in utero transfer of three embryos obtained by in vitro fertilization (IVF), with progression of the intrauterine twin pregnancy after resection of the cornual pregnancy.
Design: Technique and instrumentation.
Setting: Département de Médecine de la Reproduction, Hôpital Edouard Herriot, Lyon, France.
Patients: A 32-year-old woman, nulliparous with primary infertility for the previous 12 years due to mixed causes (tubal and male infertility).
Interventions: Diagnosis by ultrasound scan and per-laparoscopic confirmation, followed by resection of the cornual pregnancy by laparotomy.
Main Outcome Measures: Ultrasound diagnosis and follow-up of the pregnancy. Delivery.
Results: Complete ablation of the cornual pregnancy. Progression of the intrauterine twin pregnancy without difficulties until 31 weeks of gestation. Cesarean upon onset of labor. Birth of two living infants. The scar of the uterine horn, examined during the caesarean, was thick and solid.
Conclusions: The early diagnosis and surgical treatment of an ectopic pregnancy permitted the development of the intrauterine pregnancy. The risk of heterotopic pregnancy is increased by medical techniques that facilitate procreation. This risk is directly related to the number of embryos transferred. In the case of heterotopic pregnancy, the rate of progressive intrauterine pregnancy after treatment of the ectopic pregnancy is encouraging. (Fertil Steril® 2007;87:190.e1–3. ©2007 by American Society for Reproductive Medicine.)

Key Words: Heterotopic triplet pregnancy, salpingectomy, IVF-ET, surgical treatment of a cornual pregnancy

Heterotopic pregnancy is the coexistence of a pregnancy (simple or multiple) of intrauterine development and of at least one ectopic pregnancy of any topography. The incidence of heteroptopic pregnancy is increased in pregnancies obtained by in vitro fertilization (IVF) with ETs; it is estimated at 1% (1–3). Few cases of triplet pregnancy combining intrauterine twin pregnancy and simple ectopic pregnancy have been described, and in particular after bilateral salpingectomy.

We present the case of a triplet pregnancy with the development of an intrauterine twin pregnancy and of a simple right cornual pregnancy in a patient who underwent a bilateral salpingectomy. The surgical treatment of the cornual pregnancy by laparotomy permitted the development of the intrauterine twin pregnancy and the birth of two twins.

CASE REPORT

The patient was a 32-year-old woman treated at our center for primary infertility for the previous 12 years due to mixed causes (tubular combined with a masculine factor). The initial assessment showed a bilateral hydrosalpinx. The patient underwent a left salpingectomy and a right nesosalpingostomy. The first three cycles of classic IVF did not result in a pregnancy.

The fourth cycle resulted in an ectopic pregnancy for which a right salpingectomy was performed. The fifth IVF did not lead to the development of a pregnancy, despite obtaining and transferring several embryos of grade A, according to the classification proposed by Ebner et al. (4).

The sixth and last IVF succeeded in obtaining 14 embryos, 13 of which were grade A. After discussion with the couple, it was decided to transfer three embryos to the eight-cell stage. The analysis of plasmatic hCGβ was positive 12 days after the transfer, and the first ultrasound scan performed 6 weeks after egg collection showed a progressive bichorial, biamniotic twin pregnancy.

The patient returned for consultation for minor vaginal bleeding at 6 weeks of pregnancy. An ultrasound scan showed the persistence of the progressive intrauterine twin pregnancy, combined with a right cornual pregnancy containing a gestational sac and an embryo of cranio-caudal length of 14 mm (standard according to stage of pregnancy), with cardiac activity (Fig. 1). It was decided to perform a laparoscopy (Fig. 2) that confirmed the diagnosis of right cornual pregnancy. Faced with the voluminous and hypervascular character of the ectopic pregnancy, and because of

Received January 1, 2006; revised and accepted April 21, 2006.
This work was performed at the Département de Médecine de la Reproduction, Hôpital Edouard Herriot, Lyon, France.
Reprint requests: Bruno Salle, M.D., Ph.D., Département de Médecine de la Reproduction, Hôpital Edouard Herriot, 5 Place d'Arsonval, 69437 Lyon, France (FAX: 33-4-72-11-69-08; E-mail: bruno.salle@chu-lyon.fr).

Copyright ©2007 American Society for Reproductive Medicine, Published by Elsevier Inc.

FIGURE 1

Ultrasound visualisation of the intrauterine twin pregnancy and of the right cornual pregnancy at 8 WG.

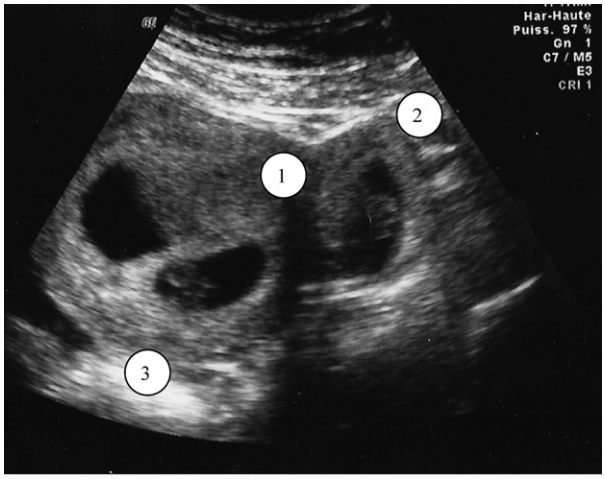

1 : intra uterine twin pregnancy
2 : heterotopic cornual pregnancy
3 : intraperitoneal liquid

Divry. Surgical treatment of cornual pregnancy. Fertil Steril 2007.

FIGURE 3

Schema of the operating technique: insertion of a tied string and resection of the cornual portion containing the ectopic pregnancy.

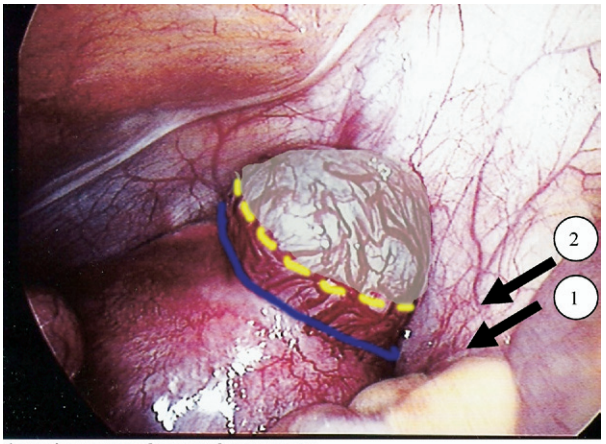

1 : string arround cornual pregnancy
2 : resection zone

Divry. Surgical treatment of cornual pregnancy. Fertil Steril 2007.

the risk of hemorrhage, the laparoscopy was converted to a laparotomy, to maintain better control of hemostasis.

We inserted a Vicryl 0™ (Johnson & Johnson, Somerville, NJ) string with a tight knot at the base of the implantation of the cornual pregnancy. We then sectioned the base of the uterine muscle above the tied string with an electric lancet. The extemporaneous macroscopic analysis allowed us to identify the trophoblastic tissue and the embryo. The cornual scar was closed by Vicryl 1™ (Johnson & Johnson) stitches in "X" form. The knot of the base was left in place (Fig. 3). Bleeding during surgery was minimal.

FIGURE 2

Per-laparoscopic confirmation of the angular pregnancy.

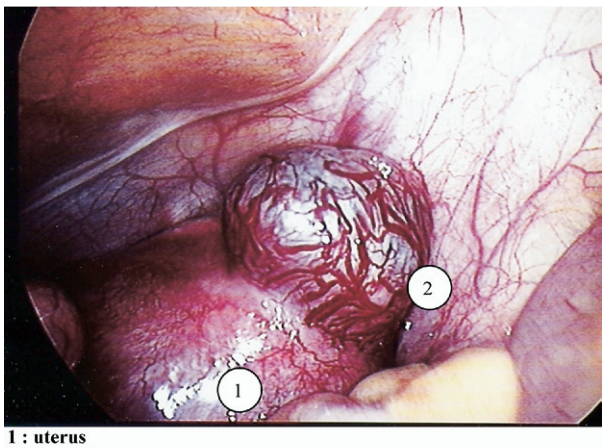

1 : uterus
2 : cornual pregnancy

Divry. Surgical treatment of cornual pregnancy. Fertil Steril 2007.

The testing of fetal vitality at days 4 and 8 after the operation showed the progressive evolution of the intrauterine twin pregnancy. There were no maternal complications. The ultrasound scan performed at 12 weeks of gestation showed normal progress of the twin pregnancy.

The patient was hospitalized at 20 weeks of gestation for surveillance of the pregnancy and strict rest. She had no uterine pain. At 31 weeks of gestation, she experienced various abdominal pains with uterine activity. At the onset of labor and because of the fragility of the uterus, it was decided to perform a cesarean section that allowed the birth of two girls weighing 1,360 g and 1,590 g and of normal development. The examination of the uterus during the cesarean section showed a solid, angular scar zone. It had the appearance of a large disc of reshaped tissue, well-vascularized, bleeding lightly upon contact, in the center of which we recognized the tied string. The associated intrauterine palpation estimated the thickness of the casing at around 1 cm. There was no sign of prerupture.

DISCUSSION

Heterotopic triplet pregnancy is an exceptional occurrence when pregnancy is obtained spontaneously (1 case out of 7,000 to 30,000) (1, 4–6). Its incidence is increased after IVF-ET, reaching a rate estimated at around 1%. An ectopic pregnancy can implant lateral to the round ligament, in the

interstitial part of the fallopian tube (interstitial pregnancy), in the uterotubal junction, in the lateral angle of the uterine cavity (medial to the round ligament), or in a rudimentary horn.

Possible risk factors are a high number of transferred embryos, a transfer near the uterine horn, excessive pressure on the syringe during the transfer, or difficulties during the ET procedure (2, 6). Bilateral salpingectomy is likely to be another risk factor for cornual pregnancy (7). For nonsalpingectomized patients, peri- and intratubular adhesions, related or not related to endometriosis, are an additional risk factor. Certain authors also consider the quality of the embryos and the hormonal milieu at the moment of transfer as possible causes (5).

The development of a pregnancy in the uterine horn creates a high risk of rupture, often very hemorrhagic because of the richness of the local vascularization through the branches of the uterine and ovarian arteries. The therapeutic objective is simple: interrupt the evolution of the ectopic pregnancy, and preserve the intrauterine pregnancy. The therapeutic options are numerous (6, 8).

The most frequently described treatment is surgical, by resection of the uterine horn by laparotomy or laparoscopy. The rate of live births is around 60%. It permits a radical treatment of the heterotopic pregnancy, but unfortunately renders the uterus more fragile. The choice of laparotomy seemed more reliable to us than laparoscopy, to ensure a solid myometrial suture, as well as a perfect hemostasis. The second option is medical treatment by ultrasound-guided injection of potassium chloride in situ, rarely combined with methotrexate because of the toxicity of the latter. This method does not render the uterus more fragile, but allows less efficient control of the interruption of the pregnancy because of the continuation of the growth of hCGβs, along with the progression of the intrauterine pregnancy (8). This method creates a risk of hemorrhage related to rupture, which limits its use to diagnoses reached before the second trimester of a pregnancy. It has the same success rate as surgical treatment. Finally, reports exist of therapeutic abstention combined with ultrasound surveillance of the spontaneous regression of the ectopic pregnancy.

In our case, because of the advanced condition of the pregnancy, the uterine horn was in a state of prerupture. No other therapeutic alternative seemed possible, although this method creates a high risk of uterine rupture because of the development of the twin pregnancy. This therapy was not conceivable without close surveillance of the pregnancy and a formal contraindication of labor. The cesarean section, performed in urgency at the onset of labor, allowed us to avoid a possible uterine rupture. We recommend systematic cesarean section before labor, to avoid a uterine rupture which may occur during delivery.

The transfer of three embryos of good quality was a major predisposing factor of the heterotopic pregnancy. Another factor was the age of the patient (<35 years).

There are many IVF cases in which a large number of embryos are transferred, and recently many salpingectomies as well. The recommendations of the American Society of Reproductive Medicine suggest limiting the transfer to two embryos of good quality for a young woman.

In conclusion, the appearance of a heterotopic pregnancy after IVF-ET remains a rare occurrence, particularly after bilateral salpingectomy. Nevertheless, it is essential to remain vigilant in order to diagnose this occurrence as soon as possible if associated symptoms appear (e.g., vaginal bleeding or pain). It is also important to respect the necessity of a systematic exploration of the pelvis upon the first ultrasound scan of the pregnancy performed at 7–8 weeks of gestation, even if there is no apparent risk factor (8). When a diagnosis is reached in time, the rate of pregnancies that reach term after treatment is encouraging. The "gold standard" treatment is still surgery (8). Finally, it seems important to limit the number of embryos transferred (9, 10), in particular with patients who present risk factors for heterotopic pregnancy.

REFERENCES

1. Dor J, Seidman DS, Levran D, Ben-Rafael Z, Ben-Shlomo I, Mashiach S. The incidence of combined intrauterine and extrauterine pregnancy after in vitro fertilization and embryo transfer. Fertil Steril 1991;55:833–4.
2. Chang Y, Lee JN, Yang CH, Hsu SC, Tsai EM. An unexpected quadruplet heterotopic pregnancy after bilateral salpingectomy and replacement of three embryos. Fertil Steril 2003;80:218–20.
3. Dumesic DA, Damario MA, Session DR. Interstitial heterotopic pregnancy in a woman conceiving by in vitro fertilization after bilateral salpingectomy. Mayo Clin Proc 2001;76:90–2.
4. Ebner T, Yaman C, Moser M, Sommergruber M, Polz W, Tews G. Embryo fragmentation in vitro and its impact on treatment and pregnancy outcome. Fertil Steril 2001;76:281–5.
5. Pan HS, Chuang J, Chiu SF, Hsieh BC, Lin YH, Tsai YL, et al. Heterotopic triplet pregnancy: report of a case with bilateral tubal pregnancy and an intrauterine pregnancy. Hum Reprod 2002;17:1363–6.
6. Kasum M, Grizelj V, Simunic V. Combined interstitial and intrauterine pregnancies after in-vitro fertilization and embryo transfer. Hum Reprod 1998;13:1547–9.
7. Agarwal SK, Wisot AL, Garzo G, Meldrum DR. Cornual pregnancies in patients with prior salpingectomy undergoing in vitro fertilization and embryo transfer. Fertil Steril 1996;65:659–60.
8. Chin HY, Chen FP, Wang CJ, Shui LT, Liu YH, Soong YK. Heterotopic pregnancy after in vitro fertilization-embryo transfer. Int J Gynaecol Obstet 2004;86:411–6.
9. Lau S, Tulandi T. Conservative medical and surgical management of interstitial ectopic pregnancy. Fertil Steril 1999;72:207–15.
10. Fernandez H, Lelaidier C, Doumerc S, Fournet P, Olivennes F, Frydman R. Nonsurgical treatment of heterotopic pregnancy: a report of six cases. Fertil Steril 1993;60:428–32.